



---

## Original research:

# Comparative evaluation of malocclusions using digital intraoral photography and conventional examination methods: A tele dentistry approach in orthodontics

Yong Chen, Shuyi Zhang, Bai Wang Liu, Shuling Guo

Department of Stomatology, School of Medicine, Xiamen University, Xiamen, China.

**Correspondence: Author:** Dr. Yong Chen, **Email:** [yongchen@xmu.edu.cn](mailto:yongchen@xmu.edu.cn);

**Tel:** 86-592-2880299



### Dr. Yong Chen

**Funding:** This study was supported by the Xiamen University Training Program of Innovation and Entrepreneurship for Undergraduates under project funding No. 2018X0583.

**Acknowledgments:** The Authors would like to thank all the participants involved in the study.

**Data Availability Statement:** The data supporting this study's findings are available from the corresponding authors upon reasonable request.

**Conflicts of Interest:** The authors declare no conflict of interest.

**How to cite this Article:** Zhang S, Chen Y, Liu BW, Guo S. Comparative evaluation of malocclusions using digital intraoral photography and conventional examination methods: A tele dentistry approach in orthodontics. *J Updates Pediatric Dent.* 2022; 1: (2): 22-28. <http://doi.org/10.54276/JUPD.2021.1205>

### Abstract

**Objective:** To analyze the accuracy and duration of oral digital photographs in evaluating malocclusion status and elucidate the feasibility of remote malocclusion diagnosis.

**Method:** Two methods [clinical examinations (CE) combined with the panoramic radiographic assessment, which was conducted as a baseline, and intraoral digital photographs examinations (IDPE), which were taken one month later] were used to evaluate the malocclusion status of 31 college students' volunteers in this one-month clinical investigation. Malocclusion examinations included: Angel's classification, overjet, overbite, upper arch space relationship, lower arch space relationship, and examination duration.

**Result:** 29 volunteers completed the whole study. The accuracy of Angel's classification, overjet, overbite, and upper and lower arch space relationship between CE and IDPE by digital photographs was 72.4%, 79.3%, 100.0%, 89.3%, and 85.7%, respectively. There were moderate consistencies in Angel's classification and overjet between CE and IDPE (Kappa = 0.46,  $P < 0.001$ ; Kappa = 0.59,  $P < 0.001$ ). There were high consistencies in the overbite, upper and lower arch crowding/spacing between CE and IDPE (Kappa = 0.92,  $P < 0.001$ ; Kappa = 0.69,  $P < 0.001$ ; Kappa = 0.66,  $P < 0.001$ ). IDPE duration was less than that of CE ( $P < 0.01$ ).

**Conclusion:** Evaluating malocclusion using digital intraoral photographs seems feasible, and remote malocclusion evaluation deserves further exploration

**Keywords:** digital photographs, malocclusion, remote diagnosis, orthodontic, accuracy

**Submitted:** 04.07.22; **Revised:** 06.09.22; **Accepted:** 31.10.22; **Published:** 12.12.22

## Introduction

Telemedicine refers to the practice of telemedicine for some common diseases through online review and analysis of case data. [1] With the popularity of the Internet, telemedicine has been explored and applied more in the initial diagnosis. [2] Telemedicine increases access and convenience of care by reallocating medical resources [3-4] and reducing the chance of nosocomial cross-infection in situations like the COVID-19 pandemic outbreak. [5] Remote diagnosis has been applied to diagnosing caries [6] and tooth injury. [7] Yuen [8] reported the application of remote video guidance in gingivitis.

As one of the three most common diseases in stomatology, the morbidity rate of malocclusion ranged from 28.8% to 83.9% worldwide. [9-11] the evidence suggests that malocclusion can not only cause headaches and other complications [12] but also affect oral function and facial aesthetics [13], which have a more significant impact on oral-related mental and physical health. [14] School-age children and adolescents were regarded as an important target group for oral health priority action [15] because some early interventions can prevent the malocclusion from worsening, reduce root resorption problems [16], obtain a well-balanced dental and skeletal development, and greatly simplify the subsequent orthodontic treatment, which is the key to the transformation of malocclusion from "treatment" to "prevention." [17] Therefore, a correct and efficient screening method is of great significance for the early diagnosis and treatment of malocclusion.

Traditional clinical evaluation is the "gold standard" of malocclusion diagnosis, but it has limitations in large-scale investigations due to financial and time constraints. [16] Therefore, finding an economical, convenient, and accurate screening method is vital for early diagnosis and preventing malocclusion. Although dental photography has become integral to the dental practice, it is rarely used to diagnose, treat, or refer to malocclusion. [6] Therefore, the study aimed to (i) to measure the accuracy and efficiency of routine clinical examinations compared with intraoral digital photo examination in malocclusion assessment and (ii) to investigate the feasibility of remote screening for malocclusion.

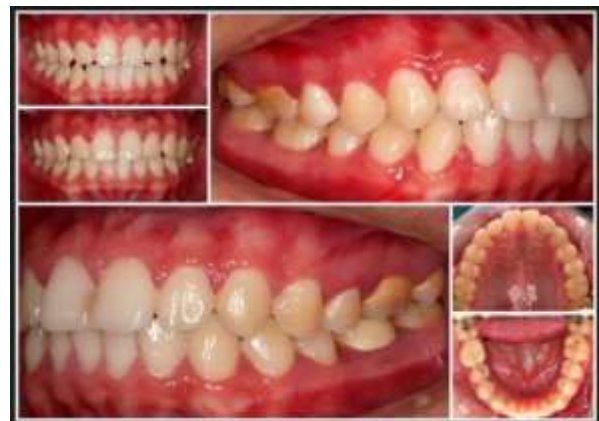## Materials and Methods

Thirty-one student volunteers from the university were recruited to perform the malocclusion assessment with the approval of the Medical Ethics Committee of the School of Medicine, Xiamen University. The subjects had the following conditions: (1) good general health; (2) good audio-

visual ability; (3) no orthodontic treatment. All the students signed informed consent agreements before the study's commencement and were entitled to withdraw from the study for any reason during the study. All examinations were performed in Xiamen Stomatological Hospital by two professional dentists, each with a timekeeper. Professional dentists took oral digital photos.

## Study Design

Two methods were used to evaluate the malocclusion status of 31 volunteers: Method 1: clinical examinations combined with the panoramic radiographic examination (CE); Method 2: intraoral digital photographs examinations (IDPE). To ensure the interexaminer consistency, a pre-test was carried out before beginning the study to calibrate the consistency of the two dentists, and the test results were relatively consistent ( $\kappa > 0.75$ ). In the first stage, two dentists performed CE of all the study subjects, and timekeepers recorded each volunteer's examination time. At the same time, dentists used flash-equipped DSLR cameras (Canon 6D with a lens of EF 100mm f) and auxiliary tools such as hooks and reflectors) take intraoral digital photos of each volunteer (Figure 1) and ensure volunteers close the bite in the proper position. A month later, the same two dentists examined the intraoral digital photographs collected before using IDPE, they were not allowed to enlarge or resize the photos, and timekeepers recorded each volunteer's examination duration.



**Figure.1 Digital intraoral photographs were taken by professional doctors using cameras with auxiliary tools.**

*Examination parameters*  
*Sagittal Anomalies*

Angle classification: Normal, the upper and lower arch is neutroclusion; class I malocclusion, the upper and lower arch is neutroclusion with malposition of the dentition; class II malocclusion, the lower arch is in the distal position; class III malocclusion, the lower arch is in the mesial position. If it was class I on one side and class II or III, it was recorded as class II or III. [17, 18]

Maxillary overjet: It was measured from the palatal surface of the mesial corner of the most protruded maxillary incisor to the corresponding mandibular incisor's labial surface. (0-3mm: normal; 3-5mm: mild; 5-8mm: moderate; > 8mm: severe).<sup>[12]</sup>

**Vertical Anomalies**

Overbite: This was graded according to the mandibular incisor's coverage by the most protruded fully erupted maxillary incisor. (Open bite: < 1 / 2; normal: > 1 / 2, < 3 / 4; mild: > 3 / 4, < 1; moderate; severe: all covering).<sup>[17]</sup>

**Space Discrepancies**

Upper arch: Crowding (0-4mm: mild; 4-8mm: moderate; > 8mm: severe), Spacing.

Lower arch: Crowding (0-4mm: mild; 4-8mm: moderate; > 8mm: severe), Spacing.

**Intraoral digital photographs**

Including (i) an intraoral frontal view of maxillary and mandibular occlusion, (ii) an intraoral photograph of edge-to-edge of dental occlusion, (iii) two lateral images (left and right), (iv) two synoptic images (maxillary arch and mandibular arch). The medical ethics committee approved this study protocol of the

School of Medicine, Xiamen University, Xiamen, China.

**Statistical analysis:**

SPSS statistical software 17.0 was used to analyze the experimental data. The analysis was performed for sensitivity, specificity, positive predictive value (PPV), negative predictive value (NPV), and accuracy.

The inter-group consistency of each examination index was calculated by kappa value, and the intergroup differences of examination time were calculated with the Wilcoxon signed-rank test. P values of less than 0.05 were considered to indicate statistical significance.

**Results**

Among 31 volunteers (with an age range of 18-22 years, a mean age of 19.3 years, and 51.6% men), twenty-nine completed the whole study, and two failed to follow up due to participants. Hence, removed from the final analysis.

**Sagittal Anomalies**

The detection number of Angle's classification and maxillary overjet were 29 and 28 in IDPE. The sensitivity, specificity, NPV,

PPV, and accuracy of the Angle's classification and maxillary overjet of IDPE compared with CE are presented in Table 1. There was moderate consistency between the two methods (Kappa = 0.46, P < 0.001; Kappa = 0.59, P < 0.001) shown in (Table 1).

**Table 1. Comparison of sagittal anomalies evaluated by two methods [clinical examinations combined with the panoramic radiographic examination (CE) and intraoral digital photographs examinations (IDPE)].**

<b>CE versus IDPE</b>	<b>Angle classification</b>	<b>Maxillary overjet</b>
Sensitivity (%)	60.0	58.3
Specificity (%)	78.9	94.1
PPV (%)	78.9	76.2
NPV (%)	60.0	87.5
Accuracy (%)	72.4	79.3
Kappa statistic (95% CI)	0.46‡	0.59‡

**PPV, positive-predictive value; NPV, negative-predictive value; CI, confidence interval.  
 Kappa statistic between groups (‡: P<0.001)**

**Table 2. Comparison of vertical anomalies by two methods [clinical examinations combined with the panoramic radiographic examination (CE) and intraoral digital photographs examinations (IDPE)].**

CE versus IDPE	Overbite
Sensitivity (%)	100.0
Specificity (%)	92.9
PPV (%)	100.0
NPV (%)	90.0
Accuracy (%)	100.0
Kappa statistic (95% CI)	0.92‡

**PPV, positive-predictive value; NPV, negative-predictive value; CI, confidence interval.  
 Kappa statistic between groups (‡:  $P < 0.001$ ).**

#### Space Discrepancies

The upper and lower arch crowding/spacing detection number was 28 and 27 in IDPE. The sensitivity, specificity, NPV, PPV, and accuracy of the upper and lower arch crowding/spacing of IDPE compared with CE are presented in Table 3. There was high consistency between the two methods (Kappa = 0.69,  $P < 0.001$ ; Kappa = 0.66,  $P < 0.001$ ). (Table 3).

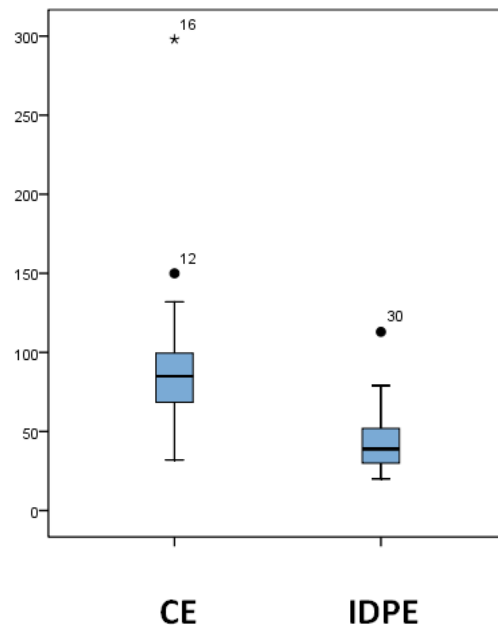
**Table 3. Comparison of space anomalies by two methods [clinical examinations combined with the panoramic radiographic examination (CE) and intraoral digital photographs examinations (IDPE)]**

CE versus IDPE	Angel classification	Maxillary overjet
Sensitivity (%)	66.7	62.5
Specificity (%)	95.7	95.0
PPV (%)	91.7	86.4
NPV (%)	80.0	83.3
Accuracy (%)	89.3	85.7
Kappa statistic (95% CI)	0.69‡	0.66‡

**PPV, positive-predictive value; NPV, negative-predictive value; CI, confidence interval.  
 Kappa statistic between groups (‡:  $P < 0.001$ ).**

#### Inspection Time

The inspection time of CE was (91.23±8.443)s, and was (43.74±8.443)s of IDPE. The difference in examination time was statistically significant ( $P < 0.001$ ). (Figure 2)



**Fig.2 Box plot diagram illustrates the examination time of malocclusion by two methods [clinical examinations combined with the panoramic radiographic examination (CE) and intraoral digital photographs examinations (IDPE)]. (\*, extreme outliers, and ·, outliers)**

### Discussion

According to the published literature, using digital photographs, the present study was considered the first to evaluate malocclusion status (including overjet, overbite, and upper and lower arch space relationship). This study aimed to evaluate the malocclusion status through intraoral digital photographs. According to Ebbinghaus's forgetting curve, after a certain period, the degree and speed of memory decline slowed down, memory became stable, and had little left after 30 days. [19] In this experiment, 30 days were taken as the interval of two examinations to reduce the interference of CE and IDPE.

The present study used Angle's classification, overjet, overbite, and upper and lower arch space relationship to evaluate the malocclusion status. It was found that the two methods had moderate consistency and accuracy in Angle's classification and overjet while having shown high consistency and accuracy in overbite and space relationships.

The main reason for this may be the shooting angle of intraoral photographs. Evidence showed that the possibility of an inaccurate diagnosis of Angle's classification increases seven times when the angle bias is 30 degrees. [20]

As the camera perspective changed and ideal photographic conditions were not possible, photographs failed to simulate clinical situations; therefore, the accuracy of Angle's classification diagnosis decreased. However, as the deviation of perspective from the perpendicular degree increased, the apparent lateral distance amplified, and a correct evaluation of the dental arch's space relationship would be more straightforward.

The overbite assessment depends on the vertical relationship between the upper and lower incisors, which was affected little by horizontal deviation. Therefore, the accuracy was moderate in Angle's classification and overjet and was high in the overbite and space relationship. Moreover, photographs can only reflect the two-dimensional plane, which is the inevitable limitation of digital diagnosis. Furthermore, for people with developed masseter, even with the help of a hook, the quality of two lateral films still needs to improve to meet the diagnosis needs. Low-quality photos increase the difficulty of diagnosis.

The remote examination benefits both parties, including healthcare professionals and patients in pandemic situations, especially the recent outbreak of COVID-19. [21-23]



This study found that the duration of IDPE was shorter compared with CE, mainly because the digital photographs had shown images required for examination, which could save the time of communication and posture preparation; second, the content of digital intraoral photographs was relatively simple and one-sided, so the information that could be obtained through the photographs was limited and spent less time. A recent Italian review stated that most emergencies, reassuring and following patients remotely in orthodontics, could be managed by teleorthodontics.<sup>[24]</sup> Furthermore, the authors opined that this teleassistance might reduce patients' office visits without compromising the outcome. The present study aimed to explore the feasibility of remote assessment of malocclusion status and improve screening scope and efficiency. This study found that compared with CE, IDPE had moderate consistency and accuracy in Angle's classification and overjet and had high consistency and accuracy in overbite and upper and lower arch space relationship. It shows that patients could get a preliminary malocclusion evaluation at home through intraoral photos. However, this clinical study had some limitations. One was that the small number of participants may cause bias. A more severe limitation was that the function of the temporomandibular joint could not be examined through photography, which is vital in orthodontics. Thus, additional studies are needed to confirm our findings.

### Conclusions

It is feasible to screen malocclusion status by intraoral digital photographs. Its high consistency and accuracy make a practical application in large-scale populations worth further study.

### References

- 1) da-Silva, C.Q.; Almeida, J.C.F. Remote diagnosis of traumatic dental injuries using digital photographs captured via a mobile phone. *Dent Traumatol*, 2017; 33(5): 350-357.
- 2) Kravets, K.; Vasylenko, O.; Dranyk, Z.; Bogomolets, O. Store-and-forward teledermatology for the most common skin neoplasms in Ukraine. *Acta Dermatovenerol Alp Pannonica Adriat*, 2018, 27(2), 79-83.
- 3) Eatai, M.; Bunt, S.M.; Kanagasigam, Y.; Kruger, E.; Tennant, M. A resource reallocation model for school dental screening: taking advantage of teledentistry in low-risk areas. *Int Dent J*, 2018, 68(4), 262-268.
- 4) Emami, E.; Kadoch, N.; Homayounfar, S.; et al. Patient satisfaction with E-Oral Health care in rural and remote settings: a systematic review protocol. *Syst Rev*, 2017, 6(1), 174.
- 5) Gong, K.; Xu, Z.; Cai, Z.; Chen, Y.; Wang, Z. Internet Hospitals Help Prevent and Control the Epidemic of COVID-19 in China: Multicenter User Profiling Study. *J Med Internet Res*, 2020, 22(4), e18908.
- 6) Estai, M.; Kanagasigam, Y.; Huang, B.; et al. Comparison of a Smartphone-Based Photographic Method with Face-to-Face Caries Assessment: A Mobile Teledentistry Model. *Telemed J E Health*, 2017, 23(5), 435-440.
- 7) InêsMeurer, M.; Caffery, L.J.; Bradford, N.K.; Smith, A.C. Accuracy of dental images for the diagnosis of dental caries and enamel defects in children and adolescents: A systematic review. *J Telemed Telecare*, 2015, 21(8), 449-58.
- 8) Yuen, H.K. Effect of a home telecare program on oral health among adults with tetraplegia: a pilot study. *Spinal Cord*, 2013, 51(6), 477-481.
- 9) Zhou, X.; Zhang, Y.; Wang, Y.; Zhang, H.; Chen, L.; Liu, Y. Prevalence of Malocclusion in 3- to 5-Year-Old Children in Shanghai, China. *Int J Environ Res Public Health*, 2017, 14(3), 328.
- 10) Bauman, J.M.; Souza, J.G.S.; Bauman, C.D.; Flório, F.M. Epidemiological pattern of malocclusion in Brazilian preschoolers. *Cien Saude Colet*, 2018, 23(11), 3861-3868.
- 11) Albakri, F.M.; Ingle, N.; Assery, M.K. Prevalence of Malocclusion among Male School Children in Riyadh City. *Open Access Maced J Med Sci*, 2018, 6(7), 1296-1299.
- 12) Komazaki, Y.; Fujiwara, T.; Ogawa, T.; et al. Association between malocclusion and headache among 12- to 15-year-old adolescents: a population-based study. *Community Dent Oral Epidemiol*, 2014, 42(6), 572-580.
- 13) Mendes de Paula Gomes, A.; Adas Saliba Garbin, C.; da Silva Ferraz, F.W.; Adas Saliba, T.; Ispier Garbin, A.J. Dentofacial deformities and implications on quality of life: presurgical multifactorial analysis in patients seeking orthognathic surgical treatment. *J Oral Maxillofac Surg*, 2019, (77)2, 409.e1-409.e9.
- 14) Sun, L.; Wong, H.M.; McGrath, C.P.J. The factors that influence oral health-related quality of life in young adults. *Health Qual Life Outcomes*, 2018, 16(1), 187.
- 15) Jiang, R.P.; McDonald, J.P.; Fu, M.K. Root resorption before and after orthodontic treatment: a clinical study of contributory factors. *Eur J Orthod*. 2010, 32(6), 693-697.

- 16) Brezniak, N.; Wasserstein, A. Orthodontic root resorption: A new perspective. *Angle Orthod*, 2016, 86 (6), 1056-1057.
- 17) Joda, T.; Bornstein, M.M.; Jung, R.E.; Ferrari, M.; Waltimo, T.; Zitzmann, N.U. Recent Trends and Future Direction of Dental Research in the Digital Era. *Int. J. Environ. Res. Public Health* 2020, 17, 1987.
- 18) Du, S.Q.; Rinchuse, D.J.; Zullo, T.G.; Rinchuse, D.J. Reliability of three methods of occlusion classification[J]. *Am J Orthod Dentofac Orthop*, 1998, 113(4), 463-470
- 19) Murre, J. M.; Dros, J. Replication and analysis of Ebbinghaus forgetting curve. *PlosOne*, 2015, 10(7), e0120644.
- 20) Jackson, T.H.; Kirk, C.J.; Phillips, C.; Koroluk, L.D. Diagnostic accuracy of intraoral photographic orthodontic records. *J Esthet Restor*. 2019, 31 (1), 64-71.
- 21) Bhumireddy, J.; Mallineni, S.K.; Nuvvula, S. Challenges and possible solutions in dental practice during and post COVID-19. *Environ Sci Pollut Res Int*. 2021, 28(2),1275-1277.
- 22) Nesenbergs, K.; Abolins, V.; Ormanis, J.; Mednis, A. Use of augmented and virtual reality in remote higher education: A systematic umbrella review. *Educ. Sci*. 2021, 11, 8.
- 23) Nuvvula S, Mallineni SK. Remote management of dental problems in children during and post the COVID-19 pandemic outbreak: A teledentistry approach. *Dent Med Probl*. 2021 Apr-Jun;58(2):237- 241. doi: 10.17219/dmp/133182.
- 24) Maspero, C.; Abate, A.; Cavagnetto, D.; El Morsi, M.; Fama, A.; Farronato, M. Available Technologies, Applications and Benefits of Teleorthodontics. A Literature Review and Possible Applications during the COVID-19 Pandemic. *J. Clin. Med*. 2020, 9, 1891.